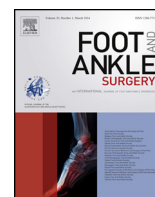




ELSEVIER

Contents lists available at ScienceDirect

Foot and Ankle Surgery

journal homepage: www.elsevier.com/locate/fas

Review

Current management options for displaced intra-articular calcaneal fractures: Non-operative, ORIF, minimally invasive reduction and fixation or primary ORIF and subtalar arthrodesis. A contemporary review

P.J. Sharr^{a,*}, M.M. Mangupli^b, I.G. Winson^c, R.E. Buckley^b^a Department of Orthopaedics, University of Otago, Christchurch Hospital, Riccarton Avenue, Christchurch 4710, New Zealand^b Department of Orthopaedics, University of Calgary, Foothills Hospital, 1403 29 St NW, Calgary, AB, Canada T2N 2T9^c Department of Orthopaedics, University of Bristol, Southmead Hospital Southmead Way, Avon, Bristol BS10 5NB, United Kingdom

ARTICLE INFO

Article history:

Received 31 January 2015

Received in revised form 27 October 2015

Accepted 30 October 2015

Keywords:

Intra-articular

Calcaneus

Fracture

Fracture management

Review article

Primary subtalar arthrodesis

Minimally invasive

ABSTRACT

Background: Management of Displaced Intra-articular Calcaneal Fractures (DIACFs) continues to be technically demanding. The literature has not been definitive in its guidance for surgeons dealing with these injuries. Recent publications have further added to the lack of clarity. This review is intended to summarise the present state of knowledge, and provide some genuine guidance for clinicians.

Objectives: To review previous research, focussing on articles published within the last fifteen years, and summarise the findings to aid surgeons in managing DIACFs with choosing best management for patients.

Methods: We reviewed the best evidence and literature, focussing on articles published within the last fifteen years, and summarised findings into workable recommendations. Variables of (1) patient, (2) the associated soft tissue injury and (3) the fracture characteristics were used to aid surgeons in choosing the best of the available options for each patient that presents with a DIACF.

Authors summary: Management of DIACFs can best be divided into four broad categories: (i) non-operative management, (ii) open reduction and internal fixation, (iii) minimally invasive reduction and fixation, and (iv) primary subtalar arthrodesis. The evolution of the literature would suggest orthopaedic surgeons managing calcaneus fractures should have an expert's knowledge, surgical expertise and the latest techniques to cover these four options, to tailor the treatment of DIACFs to the individual patient.

© 2015 European Foot and Ankle Society. Published by Elsevier Ltd. All rights reserved.

Contents

1. Introduction	2
2. Options of management	2
2.1. Non-operative management	3
2.2. Open reduction and internal fixation	3
2.3. Minimally invasive reduction and fixation	3
2.4. Primary ORIF and subtalar arthrodesis	4
3. Factors for consideration in deciding management Of DIACFs	4
3.1. Patient Factors	4
3.1.1. Co-morbidities	4
3.1.2. Age	4
3.1.3. Gender	4
3.1.4. Functional demand	4
3.1.5. Influence of litigation, compensation and cost economic effect upon decision-making	5

* Corresponding author. Tel.: +64 21962669.

E-mail address: jonnysarr@yahoo.co.nz (P.J. Sharr).<http://dx.doi.org/10.1016/j.fas.2015.10.003>

1268-7731/© 2015 European Foot and Ankle Society. Published by Elsevier Ltd. All rights reserved.

3.1.6.	Mental state	5
3.1.7.	Effect of limitation of evidence	5
3.2.	The limb and the nature of the soft tissue injury	5
3.2.1.	Open fractures	5
3.2.2.	Bilateral fractures	5
3.3.	Fracture characteristics	5
3.3.1.	Sanders classification	6
3.3.2.	Bohler's angle	6
3.3.3.	Extra-articular fractures	6
4.	Summary	7
	References	7

1. Introduction

Displaced Intra-articular Calcaneal Fractures (DIACFs) present a potentially debilitating problem for a patient and a management dilemma for most orthopaedic surgeons. The literature has not been consistent with regards to benefits of an operative intervention over non-operative management. There are trends in the literature to suggest anatomic reduction, both through the articular surfaces and shape, and stable fixation with avoidance of complications results in the best outcome in terms of earliest possible restoration of function, patient satisfaction and minimisation of post-traumatic arthritis [1–6]. Complications when trying to achieve these aims can lead to significant, painful outcomes and inability to reach desired long term function and a requirement for second surgeries [5].

An assessment of functional status (SF-36 scores) of patients with DIACFs shows significantly poorer results than those for other orthopaedic conditions and those of the normal population [7], suggesting significant long term disability after these injuries. On the other hand, studies have identified DIACFs managed non-operatively, will have an average score of 7 out of 10 on an oral analogue scale for pain, with a score of 10 reflecting no pain. When not stratified, there was no significant difference in pain or functional outcome between this group of patients and the group who underwent surgery [2,8]. Consistently, there is a trend towards less successful results with non-operative management when compared with operative management [3]. Non-operatively managed patients have a six times greater risk of requiring a salvaging subtalar arthrodesis, compared to those who have had operative management [2,9]. However, the worst outcomes are seen in patients who have had a surgical intervention, but not had an adequate reduction or who have had a significant complication [4,5]. Therefore, selection of patients into correct management directions would seem to be paramount. Two priorities are created from this information. The first priority is to identify accurately those patients that will have a good result from non-operative management, and second those who will benefit from surgery, while reducing the risks of a poor surgical result.

The UK Heel and Fracture Trial is a recent multicentre randomised controlled trial that has suggested that there is no benefit from open reduction and internal fixation for DIACFs [10]. The study did have some strong selection bias as participating surgeons had the opportunity to exclude patients with DIACFs if they felt there was clear benefit in a particular management option, including gross deformity, which was not defined. This meant that the study may well have been more representative of patients with DIACFs of less displaced fracture patterns. Patients also had the opportunity to select their management option, which is heavily dependent on the information they were likely to be provided. Of the 502 patients eligible to be involved in the trial, 70% declined to be involved with the trial, with 83% of them showing a preference for operative or non-operative care. 73 patients

received operative management, through an extensile lateral approach, from one of 27 different surgeons in one of 22 different centres. Just 51 of those patients had post-operative CTs which identified that nearly a quarter of these patients had greater than 2 mm residual step in the articular surface. Despite the potential limitations of this study, especially the inclusion of poorly reduced fractures and the high rate of complications, it is a very useful addition to the literature as it does imply some very significant limitations of a formal open reduction through an extended lateral approach and that all reductions should be checked by CT post-operatively. This study also suggests that surgery for DIACFs is difficult and should be performed by experts in the area.

Two recent published long term studies, beyond twelve years, looking at results of patients originally randomised to operative versus non-operative management have been published [6,11]. Both studies have a high drop-out rate from the original cohort of patients and are recognised to be underpowered for true statistical assessment. The authors acknowledge that techniques of reduction and fixation have progressed from the time of the original study and the aims of surgery at the time didn't adequately address the reduction of the posterior facet [11]. Also, the studies were not consistent as to whether there was an increased incidence of post-traumatic arthritis in either group, or whether that presented any clinical effect. With this in mind, the authors conclude that there is slight benefit from surgery over the long term [6]. Close review of the data presented in both studies particularly between the best results and the worst results, we feel, they showed a reasonable trend towards benefit of surgical intervention in most parameters assessed over time. With more modern surgical techniques and appropriate selection of patients and surgical technique, we feel minimisation of complications is possible and benefit of surgical intervention in the appropriate setting will be possible. This opinion seems in keeping with that of the authors of a recent meta-analysis of the published literature [12].

2. Options of management

Because of the variety of 'personalities' of calcaneal fractures, no one technique is likely to manage every calcaneal fracture. With this variability in mind, we believe that management of DIACFs can best be divided into following four broad categories:

- (i) Non-operative management
- (ii) Open reduction and internal fixation
- (iii) Minimally invasive reduction and fixation
- (iv) Primary ORIF and subtalar arthrodesis

Orthopaedic surgeons managing DIACFs should have skills for these four options, taking into account the patient, the limb and the fracture that is presenting. In the authors' experience, the

treatment of DIACF's has followed trends over the last few decades, with all methods having respect in the literature (Fig. 1).

It has been confirmed that these challenging injuries have better outcomes when managed in institutions with greater case volumes [13,14]. In fact, strong inverse relationships have been identified between rate of delayed subtalar arthrodesis performed and deep infection rates compared to institutional fracture load.

2.1. Non-operative management

In some patients with DIACFs, there are identifiable factors that decrease the expected outcome of surgical management and increase the risk of complications with operative management. In these patients, non-operative management may be preferable. Non-operatively managed patients should be treated with rest, ice, elevation, and early range of motion. Splinting should be discontinued, if used at all, and early movement of their ankle and hind foot should be started within 5 to 10 days of injury to minimise the associated hindfoot stiffness. Analgesia needs to be adequate from an early stage, as we feel the tendency for immobilisation for comfort may ultimately add to the difficulties in rehabilitation. The patient should most probably remain non-weightbearing for 6 weeks, although it is acknowledged that some authors allow partial weightbearing earlier [15]. It is of note, that there are no published studies validating any mobilisation or weightbearing protocols for calcaneus fractures. Patients with this injury should be able to return to sedentary work by 3 months and light duty work by 4 months, with return to previous employment by 6 months post injury [4,16]. Custom made orthotics may be prescribed after 4 months if needed. There is an incidence of between 10% and 16% of patients treated non-operatively requiring a secondary subtalar arthrodesis because of hind foot pain [2,6]. Some patients may require a lateral wall exostectomy for subfibular impingement symptoms [17]. However, this still means that there is an approximately 80% chance of not requiring any procedure in the future, which makes it a viable treatment option in certain circumstances.

2.2. Open reduction and internal fixation

Open reduction and internal fixation through an extended lateral approach has been the most frequently utilised technique for surgically restoring the calcaneal anatomy through the last three decades [18–22]. It remains the gold standard for fixation of the calcaneus to achieve anatomic reduction, with placement of

appropriate stable screw and plate fixation [12]. Although some studies have demonstrated a positive effect from surgery, it is important to state that there have been no well-designed high level studies proving that surgery significantly improves outcomes. The most common complications associated with open reduction and internal fixation relate to wound healing problems [10,12,23–26]. Other techniques of open reduction and fixation have been described including medial [27], combined medial and lateral [28], and sinus tarsi approaches [29–32]. The rates of complications from the extended lateral approach may be historically overstated [33], and frequently, local wound care is all that is required with no significant sequelae. However, the associated scarring and required interventions associated with the management of these wound problems likely leads to an inability to rehabilitate the patient at an early stage. These complications of surgery are likely to be reduced when done by a local expert in the area of foot and ankle trauma.

2.3. Minimally invasive reduction and fixation

Minimally invasive reduction and fixation techniques have primarily been devised because of the concern over wound healing and are becoming increasingly popular amongst the international orthopaedic community. Currently, there is no consistency in the techniques described by surgeons to meet with the criteria of being “minimally invasive”. There is also limited literature supporting the quality of intra-articular reduction achieved by these techniques. However, published reports of case series and techniques are increasing [15,29,34–42].

Minimally invasive techniques are all technically demanding in their endeavour to achieve anatomic reduction and stable fixation to allow early mobilisation. They are not designed to improve on any reduction and fixation achieved by an extended lateral approach. Each of the techniques tends to involve indirect reduction manoeuvres, relying on ligamentotaxis to achieve reduction, often through a variant of that described by Essex-Lopresti [37,43]. Depending on the nature of the fracture being addressed, joysticks and further reduction tools such as wires or pins, laminar spreaders, elevators or bone punches are used to restore the calcaneal height, length, and alignment of the calcaneus and reduce any joint depressed fragments. Minimally invasive reduction and fixation techniques are employed utilizing the intraoperative image intensifier and small incisions to place tools for accurate reduction. Disimpaction and reduction of fracture fragments to a reduced position is thought to reduce further harm.

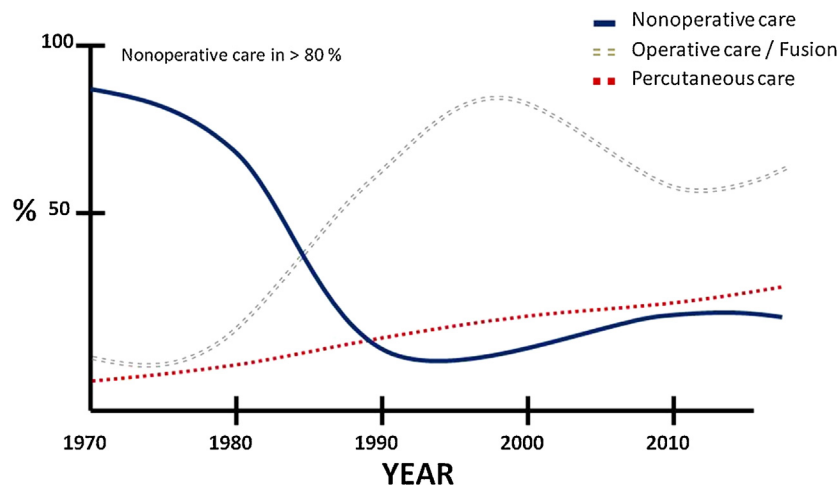


Fig. 1. Trends in management of DIACFs over the last four decades in Foothills Medical Center, Calgary Alberta Canada.

Various techniques of fixation have been described involving percutaneous k-wires or Steinman pins, percutaneous screws cannulated or solid, and percutaneous plate positioning. Intra-operative arthroscopic assessment of the subtalar joint has also been described as a further aid to assess adequacy of fracture reduction with minimally invasive reduction and fixation techniques [44,45]. These techniques can be utilised earlier in the post injury period than traditional ORIF techniques [37,38,46,47]. Minimally invasive reduction techniques are particularly appropriate for the patient who has early threats to skin and who requires reduction and fixation but may carry factors concerning to an extended lateral incision. Conversely, minimally invasive reduction and fixation techniques are limited by timeframes beyond 14 days as anatomical reduction of fracture fragments become significantly harder, as healing proceeds. No studies have confirmed exactly when minimally invasive tactics should be used for DIACFs but anatomic reductions are easier to achieve with earlier surgery.

2.4. Primary ORIF and subtalar arthrodesis

In some fractures, the articular comminution and cartilaginous injury are so significant it can be concluded that adequate joint reduction cannot be reliably achieved and primary subtalar arthrodesis may be the best management for the individual to achieve the best possible outcome [9,48–50]. Primary ORIF and subtalar arthrodesis is best done by the classical lateral extensile exposure, but may also be possible through a sinus tarsi or minimally invasive reduction and fixation technique. The main objective is to obtain restoration of the calcaneal height, width and alignment and complete debridement of the subtalar joint cartilage. The talus should be reduced from a dorsiflexed position, and the calcaneal tuberosity taken out of varus. The calcaneus is reconstructed using standard reduction and fixation techniques and the remaining articular cartilage is removed. Supplemental cancellous allograft or equivalent depending on institutional availability is placed within the subtalar joint. Definitive fixation is achieved with large, cannulated screws perpendicular to the plane of the posterior facet. Weightbearing may be initiated earlier than for those treated with ORIF or minimally invasive techniques as concerns over loss of subtalar joint congruity associated with premature weightbearing are obviously not present.

3. Factors for consideration in deciding management Of DIACFs

The selection process for experienced foot and ankle trauma surgeons, to encourage best patient outcome, is heavily dependent on (a) patient factors, (b) the limb and the nature of the soft tissue injury as well as the (c) characteristics of the fracture (Table 1).

3.1. Patient Factors

3.1.1. Co-morbidities

Patients with co-morbidities have greater risk of peri-operative complications. With regards to ORIF, as mentioned, the most common complication is related to wound healing. These are more common in, but not isolated to, patients with peripheral vascular disease, poorly controlled diabetes and smokers. There is a cumulative effect with these identified risk factors [5,51].

Patients with osteoporosis are at a risk of loss of inadequate purchase of fixation and this may lead to a loss of reduction or backing out of screws and result in skin irritation, compromise of ability to wear footwear, infection and requirement for screw removal. The presence of co-morbidities should be an influence on the treatment options where it is clear they will have a negative impact on the outcome.

Table 1
Factors for consideration in decision making for DIACFs.

Decision making	
Patient factors	Comorbidities (Diabetes, cardiovascular disease, osteoporosis) Age Gender Functional demand (Sports/Work) Smoking Litigation or compensation schemes Psychiatric disorders
Soft tissue consideration	Open fractures Severe swelling Blistering
Fracture characteristics	Bohler's angle Sanders classification Intra-/extra- articular

3.1.2. Age

In patients who are skeletally immature, extra-articular calcaneal fractures and DIACFs have traditionally been suggested to do well regardless of whether they have operative or non-operative management [52–54]. This is possibly due to most paediatric calcaneal injuries being of low-energy mechanism and extra-articular in nature [55]. However, no good trials of non-operative versus operative management in the very young have been published, with the literature being limited to case series reports. More recently, there has been an increasing acceptance that in the paediatric population, DIACFs have a lot to gain by surgical reduction and fixation. The risk of complications in this demographic is markedly reduced [56–58].

The paper published by Buckley et al., [2] showed in the subgroup analysis that patients less than 30 years of age had a significant benefit from surgical intervention. Patients over the age of 60, however, did not show a functional benefit from surgery. The theory that older patients do not benefit from surgery has been challenged by two more recent retrospective review articles [59,60]. They both identified, however, high complication rates (up to 40%) in their studies with minimum of two years follow-up, and higher incidence of radiographic subtalar arthritis (34 and 40%, respectively). They concluded that surgical intervention for these older patients results in a good range of motion, and a high degree of patient satisfaction. They also noted that it may be the presence of co-morbidities that is the precursor to a poorer outcome rather than the age of the specific patient.

3.1.3. Gender

Females under 60 years of age have been shown to have a significantly better outcome with surgical intervention than those treated non-operatively [2,61]. Young males also show a similar trend.

3.1.4. Functional demand

Those of lower functional demand for work and recreation have been suggested to not benefit from surgical intervention. A significant number of patients are manual labourers and expected to return to their previous occupation [16]. Patients with heavy workloads have been shown to have poorer outcome scores overall than those with lighter workloads, regardless of intervention, however, those treated operatively have a quicker return to work and a lower incidence of later subtalar arthrodesis [2,62]. Those young men with lighter workload, showed a significantly better outcome score with surgical management than non-operative management.

3.1.5. Influence of litigation, compensation and cost economic effect upon decision-making

It has been shown that a patient's involvement in litigation, a worker's compensation scheme or other insurance claim associated with their injury, has a negative influence on their long-term functional outcome regardless of management [2,9]. If they do have surgical intervention, they have been found to have an increased incidence of subtalar arthrodesis than patients that do not have insurance claims related to their injuries.

An economic evaluation of operative compared to non-operative management of DIACFs identified that there was a cost benefit in providing surgical management due to the quicker return to work and a lower rate of subtalar arthrodesis [63].

3.1.6. Mental state

It has been identified by the authors of the largest RCT involving DIACFs that 1 in 10 patients sustaining DIACFs have a diagnosis of a psychiatric disorder [Buckley R, personal communication, January 2014]. The prevalence of psychiatric disorder in patients with DIACFs may vary hugely in different communities, not necessarily as a result of an increase in psychiatric disease, but because of the variance in incidence of industrial or road traffic accidents being the cause of calcaneal fracture. Prolonged periods of non-weightbearing or options which increase the likelihood of second surgeries, and associated stress to the patient that presents, are probably best avoided. Primary ORIF and subtalar arthrodesis, with the earlier potential of weightbearing and probable decreased incidence of second surgeries seems advantageous in this patient group. Non-operative management presents a similar benefit to earlier weightbearing and avoidance of the associated stress of surgical management. It would seem that under these circumstances, there is an increased need to plan treatment on the basis of patient reliability and their willingness to collaborate in their treatment.

3.1.7. Effect of limitation of evidence

Given that a lot of these conclusions have been drawn from the largest randomised controlled study performed by the Canadian Orthopaedic Trauma Society over a decade ago [2,5,7,9,16], there is a significant potential for confounding as far as patient variables are concerned. The study was well constructed but had many flaws. The conclusions have been drawn from post-hoc analysis. However, there has not been a bigger prospective trial or randomised study published since. There are two other well-designed studies [6,10] that have tried to incorporate selected patient variables specifically in their study design to differentiate as to who will benefit most, and who has the least to gain from surgical or non-operative management. All 3 studies leave some room for debate as far as benefits of surgery in patients with DIACFs. It is disappointing to note, that despite the large decade old Canadian RCT setting the scientific agenda by showing that different patient characteristics are an important influence as much as the characteristics of the fracture, recent studies seem not to have developed the science further.

3.2. The limb and the nature of the soft tissue injury

Swelling about calcaneal fractures is expected. The onset of swelling is rapid and is frequently associated with ecchymosis and fracture blistering. Respect for the soft tissues is paramount and appropriate delay of timing for surgery and customisation of surgical approach is often required to avoid poor outcomes. All patients who present with DIACF, should in principle be treated initially with rest, elevation, ice and compression [64,65]. There are rare exceptions where it is clear at an early stage that the skin is under particular threat and will result in ulceration and the worst

form of open injury, the one acquired by the breakdown of soft tissues secondarily. The commonest cause of this is variants on a tongue-type fracture where the posterior skin is acutely tented over the displaced fracture fragment. These injuries require early, if not immediate, intervention. Otherwise, the duration of delay for the soft tissue injury to settle prior to surgery, is usually less than 2 weeks, however may be up to 4 weeks. Increased delay to surgical reduction and fixation beyond 14 days after injury has been suggested to increase the risk of complications [66]. Regardless, the evidence for timing is overwhelmingly in favour of allowing swelling to settle before approaching a DIACF with an open technique. Similarly, patient co-morbidities associated with lower limb swelling, venous congestion, immune-compromise, significant nutritional deficiency, or diabetes are associated with increased risk of wound complications in surgical procedures about the calcaneus [25,67]. A minimally invasive reduction and fixation technique may well provide an alternative to an open approach in patients with these risk factors, or earlier in the post-injury phase due to a lower risk of wound problems [47].

3.2.1. Open fractures

Open calcaneal fractures have a high incidence of complications [51,68]. Gustilo type III fractures have up to 50% incidence of infection and approximately half of these are osteomyelitis. Early administration of antibiotics, urgent debridement and irrigation and wound coverage are required. For Gustilo III open calcaneal fractures a musculocutaneous flap is likely required [67]. Definitive fracture stabilisation can and should wait until soft tissue coverage is complete and swelling has settled [69].

3.2.2. Bilateral fractures

No demographic difference has been identified between those patients sustaining bilateral DIACFs with those who experience unilateral DIACFs. However, some differences have been recognised. It has been identified that those patients sustaining bilateral DIACFs have a significantly more depressed Bohler's angle than in patients with unilateral DIACFs. They experience a poorer range of motion after their injuries, regardless of management, than those with unilateral injuries and they were significantly more likely to require late subtalar arthrodesis if they were treated non-operatively [70]. This implies that patients suffering bilateral injuries almost certainly have had a greater degree of energy inflicted. The relationship to other injuries needs further analysis as it is this group where there is a relationship with polytrauma.

3.3. Fracture characteristics

When calcaneal fractures are imaged carefully with CT scan, accurate diagnosis and management can be planned. The axial images highlight the extension of the fracture anteriorly, the calcaneocuboid joint, and the sustentaculum tali as well as the level of medial comminution, the alignment of the tuberosity fragment, the breadth of the heel with lateral wall "blow out" and the integrity of the sustentaculum fragment. The sagittal images allow assessment of joint fragment depression and the tuberosity fragment displacement. The anterior process involvement and rotational displacement of the superolateral fragment are also assessed. The 30° semi-coronal images allow assessment of posterior facet comminution, sustentaculum tali displacement, calcaneal body widening and associated subfibular impingement from lateral wall "blowout". The facet joint assessment allows characterisation of the fracture to be made using the classification system designed by Sanders [71]. Although all slices of coronal images are carefully evaluated, the system utilises the coronal slice at the level through the widest section of the posterior facet of the undersurface of the talus. The number of fracture fragments of

the facet joint surface delineates fractures into types I (no intra-articular fracture line), II (single fracture line with two posterior facet joint fragments), III (two fracture lines and three fragments) or IV (more than two intra-articular fracture lines within the CT slice). The type II and III fractures are then further subdivided depending on the location of the sagittal fracture line: A laterally, B centrally, C medially. The type III fractures have combinations of these to AB, AC or BC. This classification system has become widely accepted by surgeons managing calcaneal fractures around the world [72]. It is prognostic, in that increased comminution has been shown to correlate with poorer results and increased rates of subtalar fusion (especially Sanders type IV), while it is rare for later fusion in Sanders I and II fractures. This classification system also aids in planning of intraoperative requirements of reduction. Fractures that are lateral, are easier to attain reduction because they are more easily visualised through a lateral approach, where increased comminution and medially placed fractures are harder to visualise intraoperatively. The classification system has been shown to have reasonable consistency and uniformity [73,74]. Other classification systems have been described [75–81]. The Essex-Lopresti system has been identified to have prognostic value [2] and therefore may aid in management decision making. Assessing outcomes of treatment of 220 calcaneal fractures, Essex-Lopresti published in 1952 a classification system according to fracture mechanism. He divided fractures into extra-articular fractures or intra-articular fractures. The intra-articular fractures were further subdivided into “tongue type” and the more common “joint depression” type. In the tongue type fracture the secondary fracture line runs from the crucial angle of Gissane to the posterior surface of the tuberosity, subsequently a variable section of posterior facet remains attached to the posterior tuberosity. The primary fracture line separates the sustentaculum, held in place by strong medial ligaments from the rest of the calcaneus. In the joint depression type fractures, the secondary transverse fracture line exits just behind the posterior facet. The joint depression and tongue type fractures are best differentiated on a lateral radiograph, or the sagittal CT images.

Fracture pattern characteristics that are felt to have little to gain from operative management, are ones that are truly undisplaced or have minimal articular involvement with less than 2 mm of articular surface displacement. There should not be significant disruption to the calcaneal shape in length, width and alignment, nor presence of gross varus or valgus malalignment.

3.3.1. Sanders classification

Buckley et al. [2] identified that Sanders III and IV calcaneal fractures have poorer results with non-operative management compared with Sanders II. It has also been identified that Sanders III and IV fractures have a poorer prognosis with ORIF than Sanders II fractures [82]. This reflects the greater level of energy of injury and therefore disruption of calcaneus shape and joint cartilage associated with this more significant pattern of articular comminution. What is perhaps surprising is that in all groups the chance of developing radiographic arthrosis is relatively high even when the joint is well reduced [71]. The implication of this is the act of reduction has benefits which influence the outcome for the patient more than just simply restoring the joint surface. The influence of joint reconstruction on reconstructing the shape, and alignment of the calcaneus may well be a significant contributor to improving outcome factors in the function of the foot.

The treatment of comminuted intra-articular calcaneal fractures (Sanders IV) is still debated. The need for additional procedures because of the development of post traumatic osteoarthritis of the subtalar joint following a DIACF has been reported to be 23% in Sanders type III injuries but up to 73% in the

type IV fractures [49,71]. Sanders IV fractures are 5.5 times more likely to require subtalar arthrodesis than Sanders II fractures [9]. Second surgeries increase the cost of management and delay the return of level of function for the patient [4,63,82]. A multicentre randomised clinical trial comparing ORIF with primary ORIF and subtalar fusion in Sanders IV fractures did not find a difference between treatment modalities in terms of function [50]. Possibly, avoidance of a second surgery in many of these patients makes primary ORIF and subtalar fusion an option for Sanders IV fractures.

3.3.2. Bohler's angle

Significant loss of calcaneal height has been shown to have negative effect on outcome [83]. Patients with a flat or negative Bohler's angle on presentation are more likely to require a subtalar arthrodesis than those with positive initial Bohler's angle [9]. Further assessment identifies that patients with displaced intra-articular fractures and Bohler's of greater than 15° have a better outcome score than those with less than 0° [2], and those that have surgery in this subset do better again, than those treated non-operatively. Simple displaced fracture patterns (Sanders II) have better results when surgically fixed than those treated non-operatively [2,71].

3.3.3. Extra-articular fractures

True extra-articular fractures of the calcaneus, not involving the subtalar joint, account for approximately 20% of all calcaneal fractures [84].

There is no level I or II evidence to assist with the management of the extra-articular fractures. Despite not having posterior facet involvement, extra-articular fractures can have significant disruption to calcaneal shape with increase width, and loss of calcaneal height and length. A key issue is that the rotated posterior fragment may endanger posterior skin necessitating urgent surgery. This fracture type can also result in significant disability of motion, function, and comfort in footwear. Surgical correction of extra-articular fractures is frequently required to minimise these sequelae. This fracture pattern can be managed reliably with a minimally invasive reduction and fixation technique [37,85].

Table 2

Options for management vs factors for consideration for DIACFs.

		Non OP	Minimally invasive technique	ORIF	ORIF+ PSF
Comorbidities		++	+	–	–
Age	<30	–	+	++	–
	>30 <60	–	+	+	–
	>60	++	+	–	–
Gender	Male	Young	–	+	++
		Old	++	+	–
	Female	Young	–	+	++
		Old	++	+	–
Functional demand	Low	+	++	–	–
	High	–	+	++	+
Smoking		++	+	+	–
Litigation/Compensation		+	+	+	+
Soft tissue injury		+	+	+	–
Sanders classification	I	++	–	–	–
	II	+	++	++	–
	III	–	++	++	–
	IV	–	–	++	++
Extra-articular fractures		+	++	–	–
Bilateral injuries		–	+	++	–

(–): Not suggested, (+): Possible option and (++) : Strongly suggested.

4. Summary

DIACFs continue to be technically demanding injuries to manage. The literature has not been definitive in its guidance of surgeons managing these injuries. There are trends in the literature to suggest anatomic reduction and stable fixation with avoidance of complications results in the best outcome in terms of earliest possible restoration of function, patient satisfaction and minimisation of post-traumatic arthritis [8,12,86] (Table 2). The addition of new techniques to the repertoire of the surgeon is encouraging, in their potential for achieving these aims. Patient demographics, fracture characteristics and surgical expertise [87,88] will continue to drive surgical options for DIACFs. The difficulties in gaining surgical experience have to be recognised and methods of producing greater reliability explored.

Further large well designed studies involving modern surgical techniques and specifically including patient variables in study design as much as the characteristics of the fracture are necessary to challenge present day patient care paradigms.

Conflict of interest statement

The authors of this paper have no conflicts of interest to declare in the preparation and submission of this manuscript.

Funding

No sources of funding have been received for the preparation of this manuscript.

References

- [1] Richards P, Bridgman S. Review of the radiology in randomized controlled trials in open reduction and internal fixation (ORIF) of displaced intra-articular calcaneal fractures. *Injury* 2001;32:633–6.
- [2] Buckley R, Tough S, McCormack R, Pate G, Leighton S, Petrie D, et al. Operative compared with non-operative treatment of displaced intra-articular calcaneal fractures: a prospective, randomised, controlled multicentre trial. *J Bone Joint Surg Am* 2002;84:1733–4.
- [3] Bajammal S, Tornetta P, Sanders D, Bhandari M. Displaced intra-articular calcaneal fractures. *J Ortho Trauma* 2005;19(5):360–4.
- [4] Coughlin MJ. Calcaneal Fractures in the industrial patient. *Foot Ankle Int* 2000;21:896–905.
- [5] Howard J, Buckley R, McCormack R, Pate G, Leighton R, Petrie D, et al. Complications following management of displaced intra-articular calcaneal fractures: a prospective randomised trial comparing open reduction internal fixation with non-operative management. *J Ortho Trauma* 2003;17(4):241–9.
- [6] Agren P-H, Wretenberg P, Sayed_noor AS. Operative versus non-operative treatment of displaced intra-articular calcaneal fractures: a prospective, randomized, controlled multi-center trial. *J Bone Joint Surg Am* 2013;95:1351–7.
- [7] Van Tetering EAA, Buckley RE. Functional outcome (SF-36) of patients with displaced calcaneal fractures compared with SF-36 normative data. *Foot Ankle Int* 2004;25:733–8.
- [8] Randle JA, Kreder HJ, Stephen D, Williams J, Jaglal S, Hu R. Should calcaneal fractures be treated surgically? A meta-analysis. *Clin Ortho Relat Res* 2000; 377:217–27.
- [9] Cszizy M, Buckley R, Tough S, Leighton R, Smith J, McCormack R, et al. Displaced intra-articular calcaneal fractures: variables predicting late subtalar fusion. *J Ortho Trauma* 2003;17:106–12.
- [10] Griffin D, Parsons N, Shaw E, Kulikov Y, Hutchinson C, Thorogood M, et al. Operative versus non-operative treatment for closed, displaced, intra-articular fractures of the calcaneus: randomised controlled trial. *BMJ* 2014;349:g4483.
- [11] Ibrahim T, Rowsell M, Rennie W, Brown AR, Taylor GJS, Gregg PJ. Displaced intra-articular calcaneal fractures: 15 year follow-up of a randomized controlled trial of conservative versus operative treatment. *Injury* 2007;38:848–55.
- [12] Veltman ES, Doornberg JN, Stufkens SAS, Luitse JSK, van den Bekerom MPJ. Long-term outcomes of 1730 calcaneal fractures: systematic review of the literature. *J Foot Ankle Surg* 2013;52:486–90.
- [13] Poeze M, Verbruggen JPAM, Brink PRG. The relationship between outcome of operatively treated calcaneal fractures and institutional fracture load: a systematic review of the literature. *J Bone Joint Surg (Am)* 2008;90:1013–21.
- [14] Shervin N, Rubash HE, Katz JN. Orthopaedic procedure volume and patient outcomes: a systematic review of the literature. *Clin Ortho Relat Res* 2007;457:35–41.
- [15] Rammelt S, Heineck J, Barthel S, Zwipp H. Percutaneous fixation of intra-articular calcaneus fractures. *Technol Foot Ankle Surg* 2009;8:70–6.
- [16] Tufescu TV, Buckley RE. Age, gender, work capability, and worker's compensation in patients with displaced intra-articular calcaneal fractures. *J Ortho Trauma* 2001;15:275–9.
- [17] Cotton FJ. Old oscarisfractures. *Ann Surg* 1921;74:294–303.
- [18] Eastwood DM, Langkamer VD, Atkins RM. Intra-articular fractures of the calcaneum. Part II: Open reduction and internal fixation by the extended lateral trans-calcaneal approach. *J Bone Joint Surg Br* 1993;75:189–95.
- [19] Schepers T, van Lieshout EMM, van Ginhoven TM, Heetveld MJ, Patka P. Current concepts in the treatment of intra-articular calcaneal fractures: results of a nationwide survey. *Int Ortho* 2008;32(5):711–5.
- [20] Thordarson DB, Krieger LE. Operative vs non-operative treatment of intra-articular fractures of the calcaneus; a prospective randomized trial. *Foot Ankle Int* 1996;17:2–9.
- [21] Benirschke SK, Sangeorzan B. Extensive intra-articular fractures of the foot: surgical management of calcaneal fractures. *Clin Ortho Relat Res* 1993;29: 128–34.
- [22] Sanders R. Intra-articular fractures of the calcaneus: present state of the art. *J Ortho Trauma* 1992;6:252–65.
- [23] Al-Mudhaffar M. Wound complications following operative fixation of calcaneal fractures. *Injury* 2009;31:461–4.
- [24] Benirschke SK, Kramer PA. Wound healing complications in closed and open calcaneal fractures. *J Ortho Trauma* 2004;18:1–6.
- [25] Harvey EJ, Grujic L, Early JS, et al. Morbidity associated with ORIF of intra-articular calcaneus fractures using a lateral approach. *Foot Ankle Int* 2001;11:868–73.
- [26] Koski A, Kuokkanen H, Tukiainen E. Postoperative wound complications after internal fixation of closed calcaneal fractures: a retrospective analysis of 126 consecutive patients with 148 fractures. *Scand J Surg* 2005;94:243–5.
- [27] Burdeaux BD. The medial approach for calcaneal fractures. *Clin Ortho Relat Res* 1993;290:96–107.
- [28] Stephenson JR. Surgical treatment of displaced intra-articular fractures of the calcaneus: a combined lateral and medial approach. *Clin Ortho Relat Res* 1993;290:68–75.
- [29] Kilkuchi C, Charlton TP, Thordarson DB. Limited sinus tarsi approach for intra-articular calcaneus fractures. *Foot Ankle Int* 2013;34(12):1689–94.
- [30] Carr JB. Surgical treatment of intra-articular calcaneal fractures: a review of small incision approaches. *J Ortho Trauma* 2005;19:109–17.
- [31] Ebraheim NA, Elgafy H. Sinus tarsi approach with trans-articular fixation for displaced intra-articular fractures of the calcaneus. *Foot Ankle Int* 2000;21:105–13.
- [32] Holmes GB. Treatment of displaced calcaneal fractures using a small sinus tarsi approach. *Technol Foot Ankle Surg* 2005;4:35–9.
- [33] SooHoo NF, Farnig E, Krenek L, Zingmond DS. Complication rates following operative treatment of calcaneus fractures. *Foot Ankle Surg* 2011;17:233–8.
- [34] Kline AJ, Anderson RB, Davis WH, Jones CP, Cohen BE. Minimally invasive technique versus an extensile lateral approach for intra-articular calcaneal fractures. *Foot Ankle Int* 2013;34(6):773–80.
- [35] Nosewicz T, Knupp M, Barg A, Maas M, Bolliger L, Goslings JC, et al. Mini-open sinus tarsi approach with percutaneous screw fixation of displaced calcaneal fractures: a prospective computed tomography-based study. *Foot Ankle Int* 2012;33(11):925–33.
- [36] Weber M, Lehmann O, Sagesser D, Krause F. Limited open reduction and internal fixation of displaced intra-articular fractures of the calcaneum. *J Bone Joint Surg Br* 2008;90:1608–16.
- [37] Tornetta III P. Percutaneous treatment of calcaneal fractures. *Clin Ortho Relat Res* 2000;375:91–6.
- [38] Stulik J, Stehlik J, Rysavy M, Wozniak A. Minimally-invasive treatment of intra-articular fractures of the calcaneum. *J Bone Joint Surg Br* 2006;88(12): 1634–41.
- [39] Park I, Song KW, Shin S, Lee JY, Kim TG, Park RS. Displaced intra-articular calcaneal fractures treated surgically with limited posterior incision. *Foot Ankle Int* 2000;21:195–205.
- [40] Schuberth JM, Cobb MD, Talarico RH. Minimally invasive arthroscopic-assisted reduction with percutaneous fixation in the management of intra-articular calcaneal fractures: a review of 24 cases. *J Foot Ankle Surg* 2009;48:315–22.
- [41] Wang Q, Chen W, Su Y, Pan J, Zhang Q, Peng A, et al. Minimally invasive treatment of calcaneal fracture by percutaneous leverage, anatomical plate, and compression bolts—the clinical evaluation of cohort of 156 patients. *J Trauma* 2010;69:1515–22.
- [42] Tomesen T, Biert J, Frolke JPM. Treatment of displaced intra-articular calcaneal fractures with closed reduction and percutaneous screw fixation. *J Bone Joint Surg* 2011;93:920–8.
- [43] Essex-Lopresti P. The mechanism, reduction technique and results in fractures of the oscaris. *Br J Surg* 1951;39:395.
- [44] Gavlik JM, Rammelt S, Zwipp H. Percutaneous, arthroscopically-assisted osteosynthesis of calcaneus fractures. *Arch Orthop Trauma Surg* 2002;122(8):424–8.
- [45] Schuberth JM, Cobb MD, Talarico RH. Minimally invasive arthroscopically-assisted reduction with percutaneous fixation in the management of intra-articular calcaneal fractures: a review of 24 cases. *J Foot Ankle Surg* 2009;48(3):315–22.
- [46] Levine DS, Helfet DL. An introduction to minimally invasive osteosynthesis of intra-articular calcaneal fractures. *Injury* 2001;32:51–4.
- [47] Arastu M, Sheehan B, Buckley R. Minimally invasive reduction and fixation of displaced calcaneal fractures: surgical technique and radiographic analysis. *Int Orthop* 2014;38(3):539–45.

- [48] Thermann H, Hufner T, Schrott E, Held C, von Glinski S, Tscherne H. Long-term results of subtalar fusions after operative versus non-operative treatment of oscarlis fractures. *Foot Ankle Int* 1999;20(7):408–16.
- [49] Sanders R. Current concepts review. Displaced intra-articular fractures of the calcaneus. *J Bone Joint Surg Am* 2000;82:225–50.
- [50] Buckley R, Leighton R, Sanders D, Poon J, Coles CP, Stephen D, et al. Open reduction and internal fixation compared with ORIF and primary subtalararthrodesis for the treatment of sanders type IV calcaneal fractures: a randomized, multicenter trial. *J Orthop Trauma* 2014;28(10):577–83.
- [51] Folk JW, Starr AJ, Early JS. Early wound complications of operative treatment of calcaneus fractures: analysis of 190 fractures. *J Orthop Trauma* 1999;13(5):369–72.
- [52] Ceccarelli F, Faldini C, Piras F, Giannini S. Surgical vs non-surgical treatment of calcaneal fractures in children: a long term results comparative study. *Foot Ankle Int* 2000;21:825–32.
- [53] Wiley JJ, Proffitt A. Fractures of the oscarlis in children. *Clin Ortho Relat Res* 1984;188:131–8.
- [54] Schantz K, Rasmussen F. Good prognosis after calcaneal fracture in childhood. *Acta Orthop Scand* 1988;59:560–3.
- [55] Schepers T, Ginai AZ, Van Lieshout EM, Patka P. Demographics of extra-articular calcaneal fractures: including a review of the literature on treatment and outcome. *Arch Orthop Trauma Surg* 2008;128(10):1099–106.
- [56] Summers H, Kramer PA, Benirschke SK. Paediatric calcaneal fractures. *Orthop Rev (Pavia)* 2009;1(1):e9.
- [57] Petit CJ, Lee BM, Kasser JR, Kocher MS. Operative treatment of intra-articular fractures in the pediatric population. *J Pediatr Orthop* 2007;27(8):856–62.
- [58] Dudda M, Kruppa C, Schildhauer TA. Pediatric and adolescent intra-articular fractures of the calcaneus. *Orthop Rev (Pavia)* 2013;5(2):e17.
- [59] Herscovici Jr D, Widmaier J, Scaduto JM, Sanders RW, Walling A. Operative treatment of calcaneal fractures in elderly patients. *J Bone Joint Surg Am* 2005;87(6):1260–4.
- [60] Basile A. Operative versus non-operative treatment of displaced intra-articular calcaneal fractures in elderly patients. *J Foot Ankle Surg* 2010;49(1):25–32.
- [61] Barla J, Buckley R, McCormack R, Pate G, Leighton R, Petrie D, et al. Displaced intra-articular calcaneal fractures: long-term outcome in women. *Foot Ankle Int* 2004;25:853–6.
- [62] Buckley R, Meek R. Comparison of open versus closed reduction of intra-articular calcaneal fractures: a matched cohort in workmen. *J Orthop Trauma* 1992;6:195–205.
- [63] Brauer CA, Manns BJ, Ko M, Donaldson C, Buckley R. An economic evaluation of operative compared with non-operative management of displaced intra-articular calcaneal fractures. *J Bone Joint Surg Am* 2005;87(12):2741–9.
- [64] Barei DP, Bellabarba C, Sangeorzan BJ, Benirschke SK. Fractures of the calcaneus. *Ortho Clin N Am* 2002;33:263–85.
- [65] Pozo JL, Kirwan EO, Jackson AM. The long-term results of conservative management of severely displaced fractures of the calcaneus. *J Bone Joint Surg Br* 1984;66:386–90.
- [66] Rammelt S, Zwipp H. Calcaneus fractures: facts, controversies and recent developments. *Injury* 2004;35:443–61.
- [67] Aldridge III JM, Easley M, Nunley JA. Open fractures: results of operative treatment. *J Orthop Trauma* 2004;18(1):7–11.
- [68] Heier KA, Infante AF, Walling AK, Sanders RW. Open fractures of the calcaneus: soft-tissue injury determines outcome. *J Bone Joint Surg Am* 2003;85(12):2276–82.
- [69] Tennent TD, Calder PR, Salisbury RD, Allen PW, Eastwood DM. The operative management of displaced intra-articular fractures of the calcaneum: a two-centre study using a defined protocol. *Injury* 2001;32:491–6.
- [70] Dooley P, Buckley R, Tough S, McCormack B, Pate G, Leighton R, et al. Bilateral calcaneal fractures: operative versus non-operative treatment. *Foot Ankle Int* 2004;25(2):47–52.
- [71] Sanders R, Fortin P, DiPasquale T, Walling A. Operative treatment in 120 displaced intra-articular calcaneal fractures. Results using a prognostic computed tomography scan classification. *Clin Orthop Relat Res* 1993;290:87–95.
- [72] Schepers T, Ginai AZ, Van Lieshout EM, Mulder PGH, Heetveld JM, Patka P. Calcaneal fracture classification: a comparative study. *J Foot Ankle Surg* 2009;48:156–62.
- [73] Brunner A, Heeren Albrecht Hahn M, Ulmar B, Babst R. Effect of three-dimensional computed tomography reconstructions on reliability of classifications of calcaneal fractures. *Foot Ankle Int* 2012;33(9):727–33.
- [74] Furey A, Stone C, Squire D, Harnett J. Oscaldis fractures: analysis of inter-observer variability in using Sanders classification. *J Foot Ankle Surg* 2003;42(1):21–3.
- [75] Bohler L. Diagnosis, pathology and treatment of fractures of the oscarlis. *J Bone Joint Surg Am* 1931;7(9):5–8.
- [76] Palmer I. The mechanism and treatment of fractures of the calcaneus; open reduction with the use of cancellous grafts. *J Bone Joint Surg Am* 1948;30:2–8.
- [77] Zwipp H, Tscherne H, Wulker N, et al. Intra-articular fracture of the calcaneus. Classification, assessment and surgical procedures. *Unfallchirurg* 1989;92:117–29.
- [78] Crosby LA, Fitzgibbons T. Computerized tomography scanning of acute intra-articular fractures of the calcaneus. A new classification system. *J Bone Joint Surg Am* 1990;72:852–9.
- [79] Zwipp H, Baumgart F, Cronier P, et al. Integral classification of injuries (ICI) to the bones, joints, ligaments—application to injuries of the foot. *Injury* 2004;35(Suppl 2):SB3–9.
- [80] Marsh JL, Slongo TF, Agel J, et al. Fracture and dislocation classification compendium—2007: orthopaedic trauma association classification, database and outcomes committee. *J Orthop Trauma* 2007;21:S1–33.
- [81] Soeur R, Remy R. Fractures of the calcaneus with displacement of the thalamic portion. *J Bone Joint Surg* 1975;57(13):413–21.
- [82] Potenza V, Caterini R, Farsetti P, Bisicchia S, Ippolito E. Primary subtalar arthrodesis for the treatment of comminuted intra-articular calcaneal fractures. *Injury* 2010;41:702–6.
- [83] Loucks C, Buckley R. Bohler's angle: correlation with outcome in displaced intra-articular calcaneal fractures. *J Orthop Trauma* 1999;13(8):554–8.
- [84] Sanders RW, Clare MP. Fractures of the calcaneus. In: Rockwood CA, Green DP, editors. *Ed fractures in adults*. 4th ed., Philadelphia, PA: JB Lippincott; 1996. p. 2294–336.
- [85] Squires B, Allen PE, Livingstone J, Atkins RM. Fractures of the tuberosity of the calcaneus. *J Bone Joint Surg Br* 2001;83-B:55–61.
- [86] Buckley RE, Tough S. Displaced intra-articular calcaneal fractures. *J Am Acad Orthop Surg* 2004;12(3):172–8.
- [87] O'Farrell DA, O'Byrne JM, McCabe JP, Stephens MM. Fractures of the os calcis: improved results with internal fixation. *Injury* 1993;24(4):263–5.
- [88] Freeman BJ, Duff S, Allen PE, Nicholson HD, Atkins RM. The extended lateral approach to the hindfoot. The anatomical basis and surgical implications. *J Bone Joint Surg* 1998;80-B:139–42.